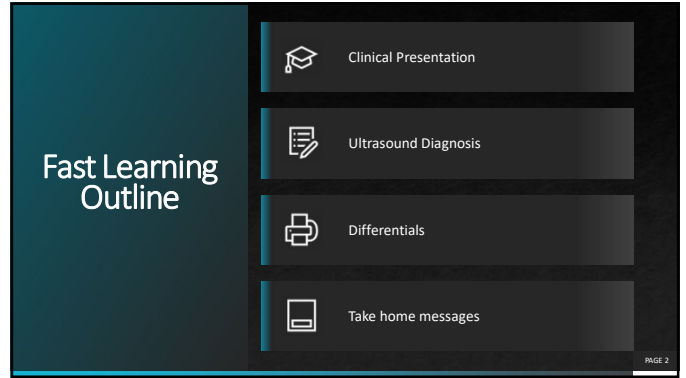
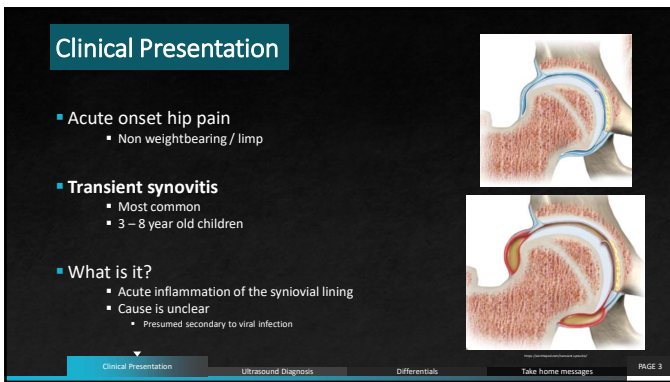


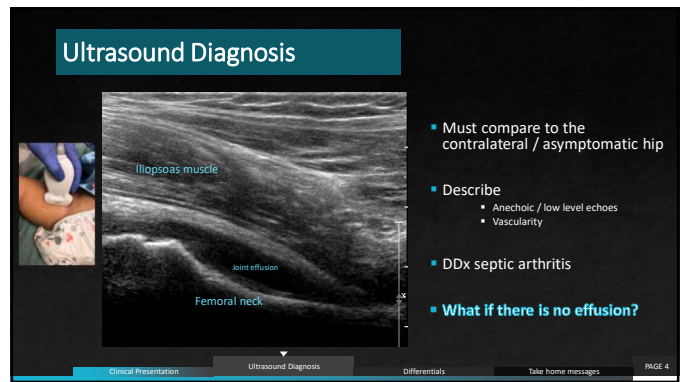
1



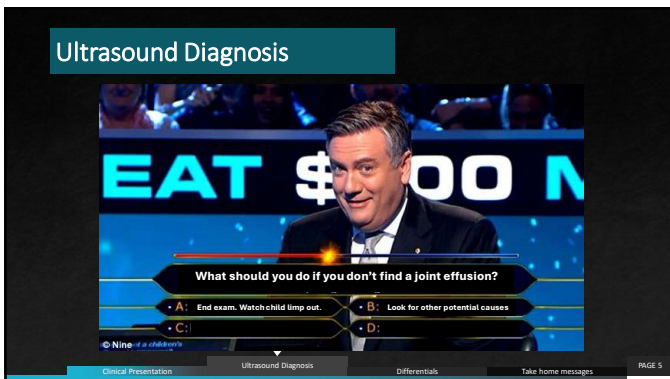
2



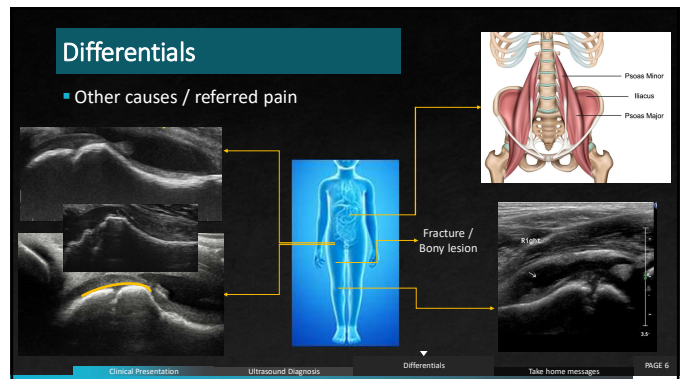
3



4



5



6

Differentials

- Other causes / referred pain

RISB
RIF LONG L-M

Clinical Presentation Ultrasound Diagnosis Differentials Take home messages PAGE 7

7

Differentials

- Other causes / referred pain

RISB
RIF LONG L-M

Appendicitis
RIF

Clinical Presentation Ultrasound Diagnosis Differentials Take home messages PAGE 8

8

Differentials

- Other causes / referred pain

RISB
RIF LONG L-M

Appendicitis
RIF

Clinical Presentation Ultrasound Diagnosis Differentials Take home messages PAGE 9

9

Differentials

- Joint
 - Transient synovitis
 - Septic arthritis

Clinical Presentation Ultrasound Diagnosis Differentials Take home messages PAGE 10

10

Differentials

Joint	Bone	Muscular	Abdominal
Transient synovitis	Perthes disease	Myositis	Inflammatory change
Septic arthritis	Slipped capital femoral epiphysis	Abscess	• Appendicitis
Haemarthrosis	Undiagnosed fracture	• Psoas	• Ileitis
Knee joint effusion	Bone tumours	• Iliacus	Pyelonephritis
			Tumour

Clinical Presentation Ultrasound Diagnosis Differentials Take home messages PAGE 11

11

Fast Learning Summary

Take home messages:

- Classic presentation – Acute hip pain / non weightbearing child
- Transient synovitis is most common
- Very important to assess for other causes or a referred source of pain

Clinical Presentation Ultrasound Diagnosis Differentials Take home messages PAGE 12

12